

A rare case of abdominal pain

Vítor Devezas^a , Pedro Amoroso Canão^b, Laura Elisabete Barbosa^a 

How to cite: Devezas V, Canão PA, Barbosa LE. A rare case of abdominal pain. *Autops Case Rep* [Internet]. 2019;9(2):e2019088. <https://doi.org/10.4322/acr.2019.088>

DEAR EDITOR

We describe herein an unusual cause of recurrent lower abdominal pain of the young male, which is rare and therefore maybe misdiagnosed and scarcely reported.

A 23-year-old man with continuous pain in the lower abdominal quadrants (predominantly the left lower quadrant) over the last month, without identifiable maneuvers that cause relief or worsen the pain. He also referred increasing urinary frequency. He denied fever, weight loss, or changes in bowel habits. His past medical history included the diagnosis of a solitary kidney (congenital renal agenesis).

The physical examination depicted a soft and depressible abdomen, which was painful on palpation in both lower quadrants, without any mass, swelling, or signs of peritoneal irritation.

The ultrasound showed a simple cystic image in the pelvis, adjacent to the left common iliac vessels, with the maximum size of 40 mm. The computed tomography (CT) scan confirmed left renal agenesis (Figure 1), and revealed marked dilation of the left seminal vesicle, with cystic formation at its extremity, measuring 43 × 44 × 47 mm (Figure 1). Thereby the hypothesis of Zinner syndrome (ZS) was raised. With this working diagnosis, the patient was submitted to a laparoscopic excision of the seminal vesicle, which was uneventful. The pathological anatomy report confirmed the presence of a seminal vesicle cyst without malignancy (Figure 2).

Acute abdominal pain in the lower quadrants, in males, may be caused by a rare condition as the Zinner syndrome (ZS).^{1,2}

In 1914, A. Zinner^{3,4} described the syndrome, which was later named after him. This syndrome is characterized by the association of a triad of Mullerian duct abnormalities, comprising the congenital unilateral renal agenesis, an ipsilateral seminal vesicle cyst, and an ipsilateral ejaculatory duct obstruction. ZS is rare and presents the incidence of 0.00464% in men.^{5,6} The ZS description comprises the seminal vesicle cyst with ipsilateral renal agenesis and obstruction of the ejaculatory duct with an ectopic ureter.^{7,8} According to Maehana et al.,⁹ to date, just over 200 cases of ZS have been described. It is considered the male counterpart of the Mayer-Rokitansky-Kuster-Hauser syndrome of females. Although the description—and most cases—involve the organs of the same side of the body, four cases have been reported with contralateral renal agenesis.⁸

This development anomaly is rare and generally asymptomatic. The ZS results from an insult occurring between the 4th and 13th gestational week.^{10,11} However, other authors refer the insult (such as mutation of metanephric blastema, or disruption of retinoic acid signaling)⁴ as occurring before the 7th week of gestation as a preponderant factor.^{3,4}

This anomaly is the result of an incomplete migration of the ureteric bud that fails to fuse with the

^a Centro Hospitalar Universitário de São João, Department of Surgery. Porto, Portugal.

^b Centro Hospitalar Universitário de São João, Department of Pathology. Porto, Portugal.



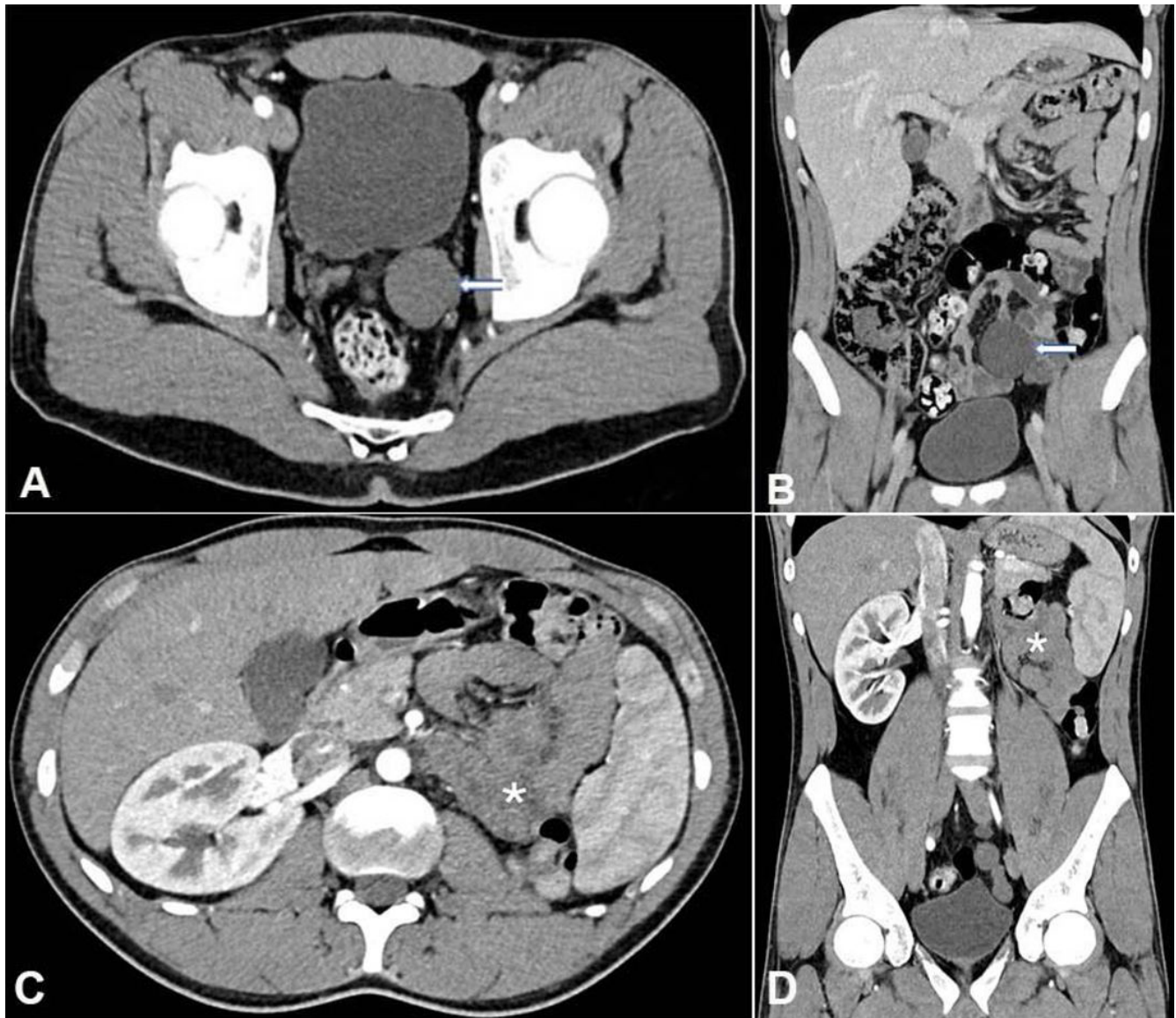


Figure 1. abdominopelvic CT. **A** – axial plane; **B** – Coronal plane – showing seminal vesicle cyst (arrow); **C** – axial plane; **D** – Coronal plane – showing left renal agenesis (asterisk).

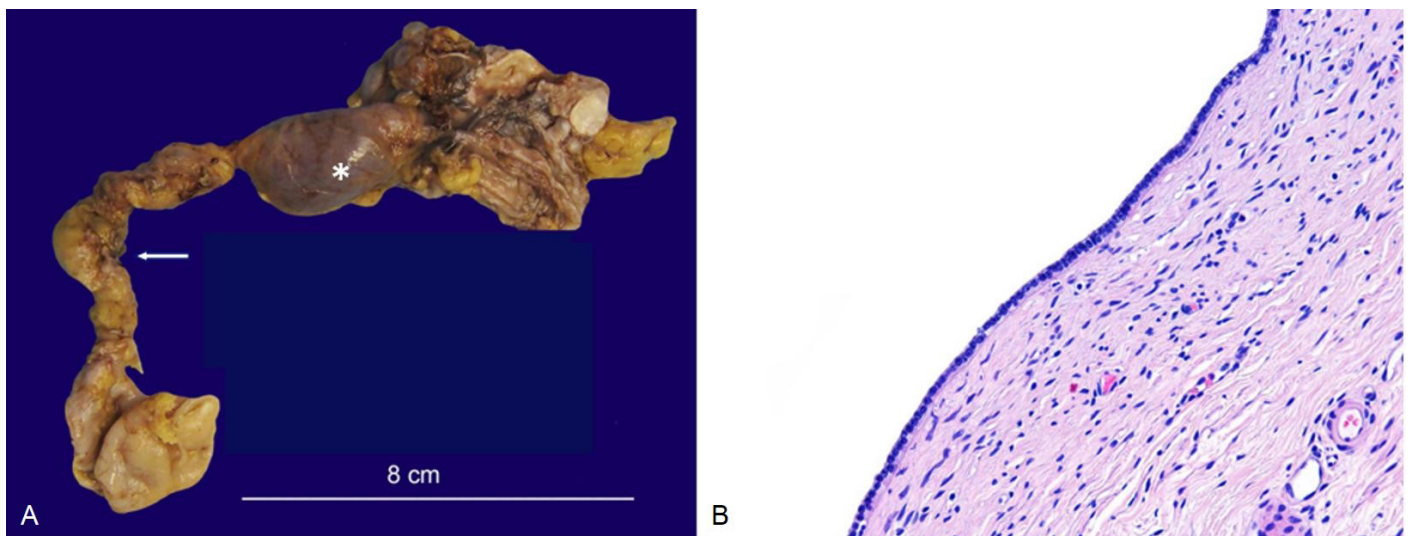


Figure 2. **A** – Gross view of the left seminal vesicle (arrow) and cyst (asterisk); **B** – Photomicrograph of the cystic wall lined by cuboidal epithelium without atypia and a mild lymphocytic infiltration of the cyst wall consistent with a seminal vesicle cyst (HE, 200x).

metanephros, which leads to renal agenesis/dysplasia, atresia of the ejaculatory duct, and obstruction and cystic dilatation of the seminal vesicle.¹⁰

The symptomatic cases are characterized by perineal pain, painful ejaculation, lower urinary tract symptoms, and other urinary symptoms.^{9,12} Van den Ouden et al.¹³ described dysuria (37%), urinary frequency (33%), perineal pain (29%), epididymitis (27%), and pain after ejaculation (21%) as the main complaints in a series of 52 patients with the diagnosis of ZS. Abdominal pain is a rare symptom of ZS. When present in the suprapubic or lower quadrant, it can be explained by ureterocele or seminal vesicle cyst growth, which elicits an inflammatory reaction in the surrounding viscera.⁹

The diagnosis of ZS can be incidental, such as in the work-up of infertility.¹³⁻¹⁵ Malignant transformation in the seminal vesicle cyst is rarely reported.⁴

The symptoms, when present, start by the second to fourth decade of life (during highest sexual activity), and mostly when cysts exceed 50 mm.^{3,5,10,16} Our patient is in the third decade of life, and the cyst was 47 mm. He presented mainly with continuous abdominal pain in the lower quadrants and frequent urination.

The differential diagnosis of cystic image in the pelvis in males includes: cyst or cystic dilatation of the prostatic utricle, ejaculatory duct cysts (all three in midline), abscess, ectopic ureterocele, prostatic cysts, ejaculatory duct cyst, diverticulosis of the ampulla of the vas deferens, and all cystic pathology of the seminal vesicle (mega vesicles, hydatidic cyst, hemorrhage, and hypotonic neuropathy).^{7,17}

The diagnostic work-up and the differential diagnosis may be aided by several imaging modalities, such as like abdominal or transrectal ultrasonography, which show the cystic nature and evaluate the relationships with pelvic organs. An abdominopelvic CT scan is better to confirm renal agenesis and to define the anatomy of pelvic structures. Magnetic resonance imaging is better than CT in delineating the anomalies, in demonstrating peripheral pelvic structures, and in planning the surgery.^{12,16,17}

The treatment of ZS depends on the presence or absence of symptoms as well as the cyst size. In an asymptomatic patient, the treatment can be conservative with follow-up. For symptomatic patients

or cysts greater than 50 mm, the best approach is laparoscopic (as proposed to our patient) or robotic techniques, with surgical excision of the seminal vesicle cysts.^{9,12,17} These techniques can relieve the symptoms while preserving fertility and erectile function.^{17, 18}

CONCLUSION

We highlight the diagnosis of ZS when a clinician is facing a young male patient with a history of renal agenesis who complains of chronic or recurrent abdominal pain. ZS is a rare condition of abdominal pain, but its correct diagnosis allows the appropriate treatment, which can be minimally invasive surgery in the symptomatic patient or if the cyst is greater than 50 mm.

Keywords

Kidney Diseases; Seminal Vesicle Secretory Proteins; Congenital Abnormalities; Solitary Kidney; Abdominal Pain.

REFERENCES

1. Ansari P. Acute abdominal pain. MSD Manual; 2017 [cited 2018 Sept 17]. Available from: www.msmanuals.com
2. Greenberger NJ. Chronic abdominal pain and recurrent abdominal pain. MSD Manual; 2018 [cited 2018 Sept 17]. Available from: www.msmanuals.com
3. Mehra S, Ranjan R, Garga UC. Zinner syndrome: a rare developmental anomaly of the mesonephric duct diagnosed on magnetic resonance imaging. *Radiol Case Rep.* 2016;11(4):313-7. <http://dx.doi.org/10.1016/j.radcr.2016.04.002>. PMID:27920851.
4. Ghonge NP, Aggarwal B, Sahu AK. Zinner syndrome: a unique triad of mesonephric duct abnormalities as an unusual cause of urinary symptoms in late adolescence. *Indian J Urol.* 2010;26(3):444-7. <http://dx.doi.org/10.4103/0970-1591.70592>. PMID:21116373.
5. Fabri TF, Neto CA, Akl MA, Dini FS. Síndrome de Zinner: relato de caso clínico. *Revista Urominas.* 2018;5(12):48-9.
6. Sheih CP, Hung CS, Wei CF, Lin CY. Cystic dilatations within the pelvis in patients with ipsilateral renal agenesis or dysplasia. *J Urol.* 1990;144(2 Pt 1):324-7. [http://dx.doi.org/10.1016/S0022-5347\(17\)39444-2](http://dx.doi.org/10.1016/S0022-5347(17)39444-2). PMID:2197430.
7. Dagur G, Warren K, Singh N, Khan SA. Detecting diseases of neglected seminal vesicles using imaging modalities: A review of current literature. *Int J Reprod Biomed.* 2016;14(5):293-302. <http://dx.doi.org/10.29252/ijrm.14.5.293>. PMID:27326413.

8. Khanduri S, Katyal G, Sharma H, Goyal A, Singh N, Yadav H. Unique association of multiple seminal vesicle cysts with contralateral renal agenesis: a rare variant of Zinner syndrome. *Cureus*. 2017;9(7):e1415. <http://dx.doi.org/10.7759/cureus.1415>. PMID:28875088.
9. Maehana T, Fukuta F, Kobayashi K, Hirobe M, Tanaka T, Masumori N. Laparoscopic surgery for seminal vesicle cysts and ureterocele with urination disorder: a case report of Zinner syndrome. *J Endourol Case Rep*. 2018;4(1):35-8. <http://dx.doi.org/10.1089/cren.2018.0008>. PMID:29588919.
10. Pavan N, Bucci S, Mazzon G, Bertolotto M, Trombetta C, Liguori G. It's not always varicocele: a strange case of Zinner syndrome. *Can Urol Assoc J*. 2015;9(7-8):E535-8. <http://dx.doi.org/10.5489/cuaj.2451>. PMID:26279734.
11. Kanavaki A, Vidal I, Merlini L, Hanquinet S. Congenital seminal vesicle cyst and ipsilateral renal agenesis (Zinner syndrome): a rare association and its evolution from early childhood to adolescence. *European J Pediatr Surg Rep*. 2015;3(2):98-102. <http://dx.doi.org/10.1055/s-0035-1555605>. PMID:26788458.
12. Fiaschetti V, Greco L, Giuricin V, et al. Zinner syndrome diagnosed by magnetic resonance imaging and computed tomography: role of imaging to identify and evaluate the uncommon variation in development of the male genital tract. *Radiol Case Rep*. 2016;12(1):54-8. <http://dx.doi.org/10.1016/j.radcr.2016.10.007>. PMID:28228879.
13. Van den Ouden D, Blom JH, Bangma C, de Spiegeleer AH. Diagnosis and management of seminal vesicle cysts associated with ipsilateral renal agenesis: a pooled analysis of 52 cases. *Eur Urol*. 1998;33(5):433-40. <http://dx.doi.org/10.1159/000019632>. PMID:9643661.
14. Pastuszak AW, Font MD, Case JR, Lipshultz LI. An infertile male with dilated seminal vesicles due to functional obstruction. *Asian J Androl*. 2017;19(2):256-7. <http://dx.doi.org/10.4103/1008-682X.179858>. PMID:27320475.
15. Aghaways I, Ahmed S. Endourologic intervention for management of infertility in a man with Zinner syndrome resulting in a natural pregnancy. *J Endourol Case Rep*. 2016;2(1):71-3. <http://dx.doi.org/10.1089/cren.2016.0010>. PMID:27579422.
16. Lin L, Guan J, Jiang X-S, et al. Zinner's syndrome: clinical features and imaging diagnosis. *Asian J Androl*. 2018;20(3):316-7. http://dx.doi.org/10.4103/aja.aja_21_17. PMID:28695865.
17. Sundar R, Sundar G. Zinner syndrome: an uncommon cause of painful ejaculation. *BMJ Case Rep*. 2015;2015(1):bcr2014207618. <http://dx.doi.org/10.1136/bcr-2014-207618>. PMID:25750220.
18. Benyó M, Berczi C, Jozsa T, Csanadi G, Varga A, Flasko T. Fertility preservation in cases of laparoscopic treatment of seminal vesicle cysts. *Cent European J Urol*. 2012;65(3):144-5. <http://dx.doi.org/10.5173/ceju.2012.03.art9>. PMID:24578951.

Author contributions: Devezas V, Canão PA and Barbosa LE had equally contributed to this article. All authors proofread the final version and approved it for publication.

The authors retain an informed consent signed by the patient authorizing the publication of this article, and the manuscript is by the Institutional Ethics Committee.

Conflict of interest: None

Financial support: None

Submitted on: April 7th, 2019

Accepted on: May 14th, 2019

Correspondence

Vítor Devezas

Department of Surgery - Centro Hospitalar Universitário de São João

Alameda Prof. Hernâni Monteiro – Porto – Portugal

CEP: 4200-319

Phone: +351 937-427-911/Fax: +351 225-025-766

vitor.devezas7@gmail.com